

All-on-four treatment in an atrophic mandible using dynamic guided surgery

Dr Jacques Vermeulen, France

The all-on-four technique for dental implant treatment is universally recognised for its efficacy, yet its applicability for atrophic mandibles remains problematic for many implant surgeons. Implant placement in such clinical situations requires high precision to avoid anatomical structures such as the mental foramina and to ensure that the bone volume around the implants is sufficient for osseointegration.

Case description

The 70-year-old female patient described in this report had undergone chemotherapy and radiotherapy in 2014 for breast cancer. She also suffered from pulmonary problems related to smoking. At the time of consultation, she was considered to be in remission and was in good general health. After a visit to her primary physician and undergoing blood work, she was cleared for implant surgery. She had previously had a poor experience with a prosthesis stabilised on four implants and reported that she was depressed because of her oral infirmity, which prevented her from eating normally. She desired fixed mandibular and maxillary restorations; thus, more appropriate fixed, screw-retained prostheses were proposed. We suggested starting the treatment in the mandible and fabricating a removable maxillary denture compatible with the new occlusal conditions. An all-on-four maxillary procedure would be performed at

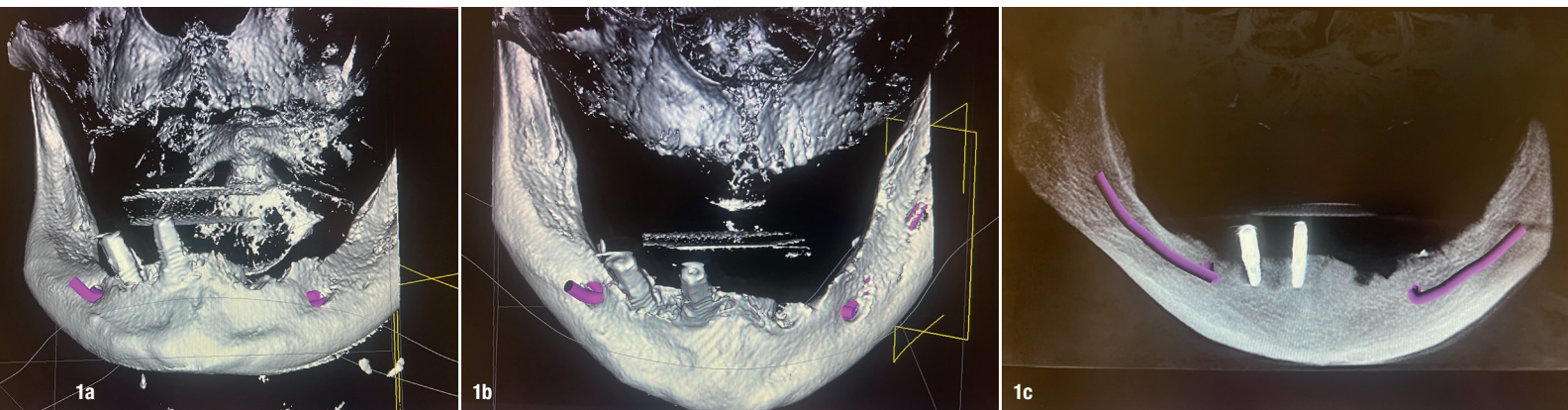
a later stage. At the initial examination, two implants had already been lost, just several months after placement of the stabilised prosthesis. A third implant had to be removed during this same session, as it caused the patient pain. Only one of the implants could be saved (Fig. 1).

Surgical preparations

Management of an atrophic mandible and an implant-supported prosthesis is an additional constraint for accurate implant positioning. Dynamic guided surgery is the only means to meet this challenge, as it permits the predictable result required for rapid loading of a transitional metal–resin prosthesis within 48 hours.

Vitamin D supplements were prescribed prior to implant surgery and the patient was asked to refrain from smoking, starting three weeks before surgery. Preoperative medication consisted of 100mg hydroxyzine hydrochloride (Atarax) and 50mg Loprazolam (Havlane) several hours before surgery, and nitrous oxide was administered on-site as required. These preoperative drugs are given so that the patient is as calm and relaxed as possible during the surgery.

The various steps described in this section all take place during the same session.



Figs. 1a–c: Pre-op CBCT scan for diagnostic purposes.

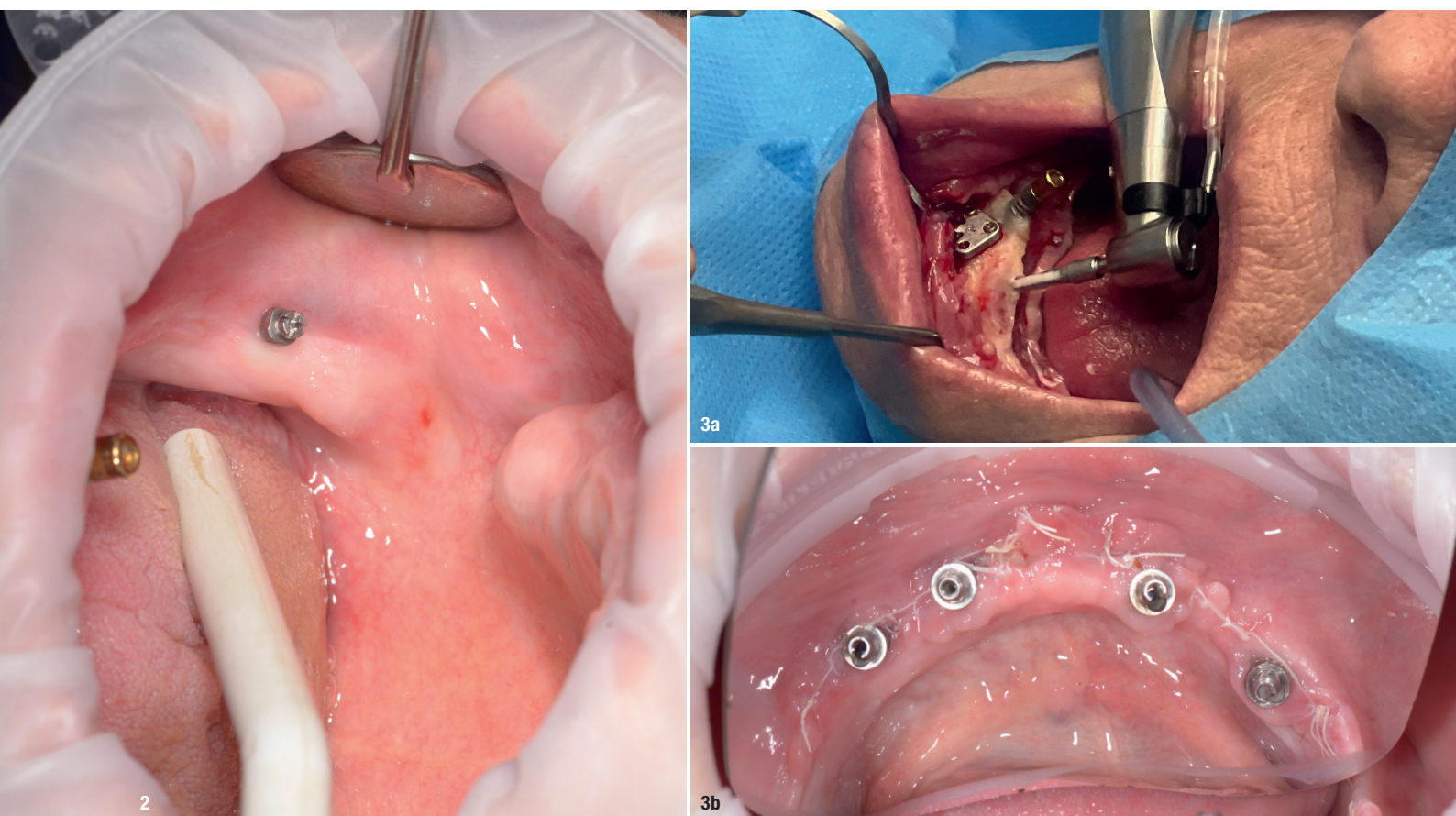


Fig. 2: Bone screw inserted as an intra-oral landmark for registration. **Figs. 3a & b:** Fixation of the Navident Jaw Tracker B in the patient's mouth.

Preparation of intra-oral landmarks for registration

For completely edentulous cases, bone screws provide an easy-to-use solution for registration landmarks—landmarks that are apparent both in the patient's mouth and in the CBCT scan and serve as reference points for the purpose of surgical navigation. In dentate cases, registration is normally performed using the existing teeth in the arch. We use three to six teeth which meet all the required criteria as landmarks. We then use an optically trackable tracer, with a spherical tip, to perform a short trace over the jaw surface, starting at each landmark location. When these teeth are not available, bone screws can be used instead. In this case, one remaining implant was used as a reference for matching purposes, along with two 7.0×1.8mm bone screws. These bone screws were placed occlusally at gingival level (Fig. 2).

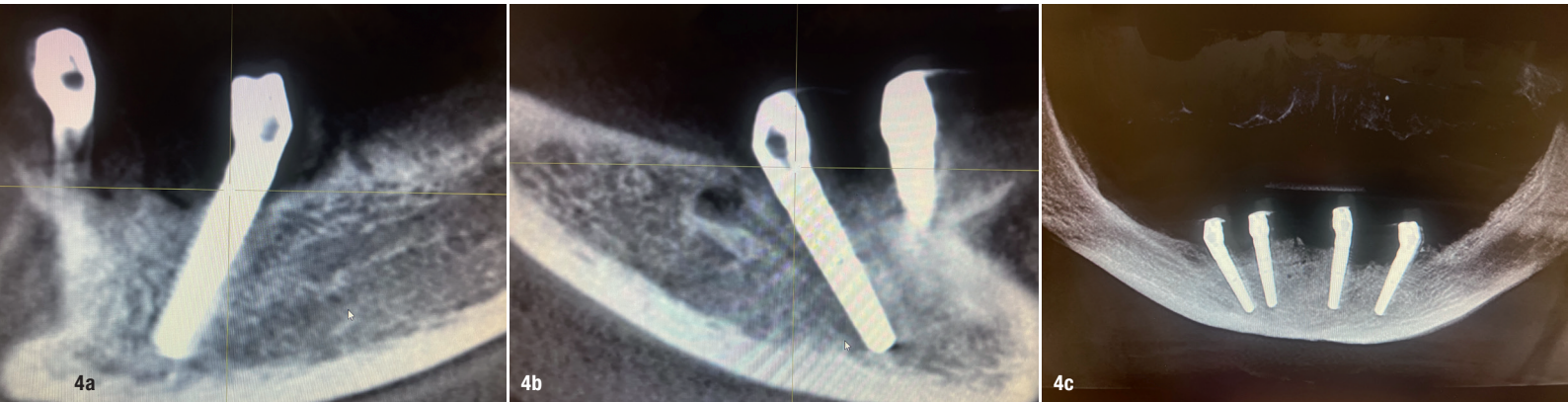Preparation of a well-fitting definitive denture or intermediate replica

The purpose of this step is to create a digital replica of the denture (STL file), accurately placed on the patient's jaw (DICOM file), to allow for the top-down planning of the supporting implants in Navident (ClaroNav), making

use of the prosthesis and the available underlying alveolar bone. This is done by introducing physical, radiopaque landmarks on to the denture which can be clearly seen in both the surface scan and the CBCT scan and hence used to match the two together. We make use of 1 mm Suremark stickers to add radiopaque markers to the denture. These peel-and-stick, artefact-free radiopaque markers are very effective and simple to use. They are affixed to the denture with a special adhesive and are easily removed after scan completion. Alternatively, gutta-percha or glass-ceramic markers, which are highly radiopaque, but do not generate scatter artefacts, could have been used.

CBCT and surface scan

After placement of the bone screws in the patient's jaw, a CBCT scan of the patient wearing the marked denture is taken. It is important to ensure that the denture is accurately seated on the patient's jaw and that the patient is stabilised in the CBCT scanner and seated and that his or her head is stabilised using a chin rest. In this case, a bite stick is less optimal, as it may cause slight dislocation of the denture. The denture should be evaluated to confirm complete seating and ideal positioning. If incomplete seating occurs, a radiolucent airspace will be seen in the CBCT scan.



Figs. 4a–c: CBCT scan post-op.

The surface scan of the denture is performed when it is outside of the patient's mouth. The scan is taken using an intra-oral scanner. The CBCT and surface scans were taken in the same session to ensure that the Suremark stickers remained in the same place. After taking both scans, the stickers were removed.

Planning the supporting implants

The CBCT scan is imported into Navident, followed by importing of the surface scan. The Navident software will allow for the accurate matching of the denture's surface scan with the CBCT scan, based on the reference landmarks in the DICOM file. The supporting implants were planned based on the denture's surface scan and the underlying bone, both demonstrated a good match on the screen.

Surgical appointment

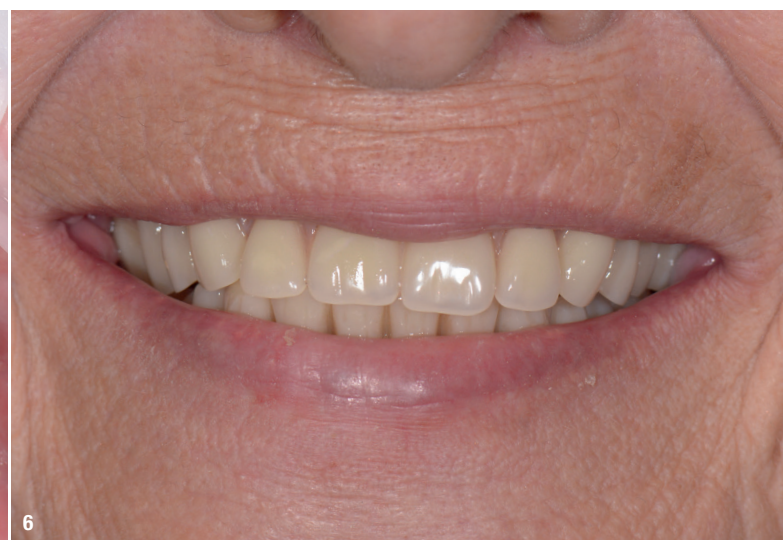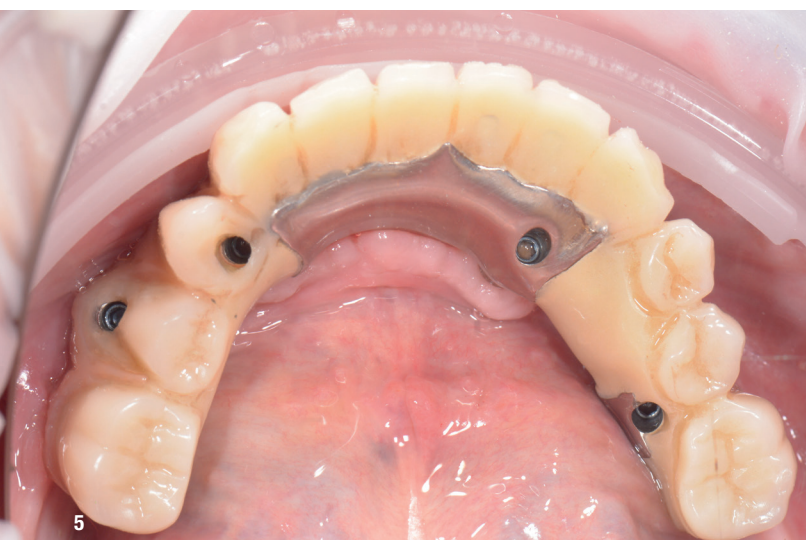The Navident Jaw Tracker B is secured in position with bone screws. In maxillary cases, the head tracker may be used instead. Registration of the patient's CBCT scan

with the patient's jaw is performed by pair-point registration using the bone screws placed in the patient's jaw prior to taking the CBCT scan. With pair-point registration, the software will automatically detect the screws when they are being located by the tracer in the patient's mouth. This ensures accurate guidance (Fig. 3). Prior to surgery, an accuracy check was performed. In this case, it was done by touching the gingiva or preferably bone crest. The bone screws were removed after implant placement (Fig. 4). After the implant placement, several sutures were placed using #4/0 PTFE thread.

The entire procedure, from the moment the patient entered the office to when she left, took only 2.5 hours. She underwent a photo-biomodulation session before she left the office, as this analgesic, anti-inflammatory and cicatrisation technique helps prevent postoperative inflammation and swelling.

Prosthetic considerations

After treatment, transfers are placed on the four multi-unit abutments and are joined together with a resin such



Figs. 5 & 6: Prosthetic and functional result.

as LuxaBite (DMG). Thin metal rods are utilised to reinforce the impression. An alginate is used for an impression of the soft tissue. Although an optical impression is also possible, fabrication of a 3D-printed master model takes much longer than use of plaster, and we prefer this last, more traditional technique. The occlusal bite is taken using the wedge prepared previously. The prosthesis was put in place 48 hours later, the passive fit was checked radiographically and any required occlusal adjustments were made (Figs. 5 & 6).

Follow-up

The patient was seen again after ten days to remove the sutures, after 30 days for a general check-up and after two months for screw tightening and obturation of the screw access holes. The patient is now seen once a year for a check-up that involves removal of the prosthesis, 660nm laser disinfection of the abutments and use of hydrogen peroxide.

Conclusion

Dynamic guided surgery permits the successful management of clinical situations characterised by severe bone loss. Without this technology, this patient would have required bone grafting and would have been without a denture for eight months to avoid pressure on the grafted sites. After the previous failures she had gone through, this was completely out of the question. Furthermore, as this technique is compatible with flapless or mini-flap surgery, the incidence of postoperative complications is reduced.

about the author



Dr Jacques Vermeulen studied at the dental school of the Université Nice Sophia Antipolis (now the Côte d'Azur University) in Nice in France. After graduating, he opened his own dental office in the village of Flumet near Chamonix in France. Dr Vermeulen's education includes postgraduate studies in prosthodontics, implantology, basal implantology, medical

emergencies at the dental office and facial anatomy at various universities around the globe. Dr Vermeulen has taught numerous postgraduate dental surgery and implantology seminars and performed live surgeries all over the world.

contact

Dr Jacques Vermeulen

dentiste.flumet@wanadoo.fr

www.cabinet-dentaire-flumet.fr